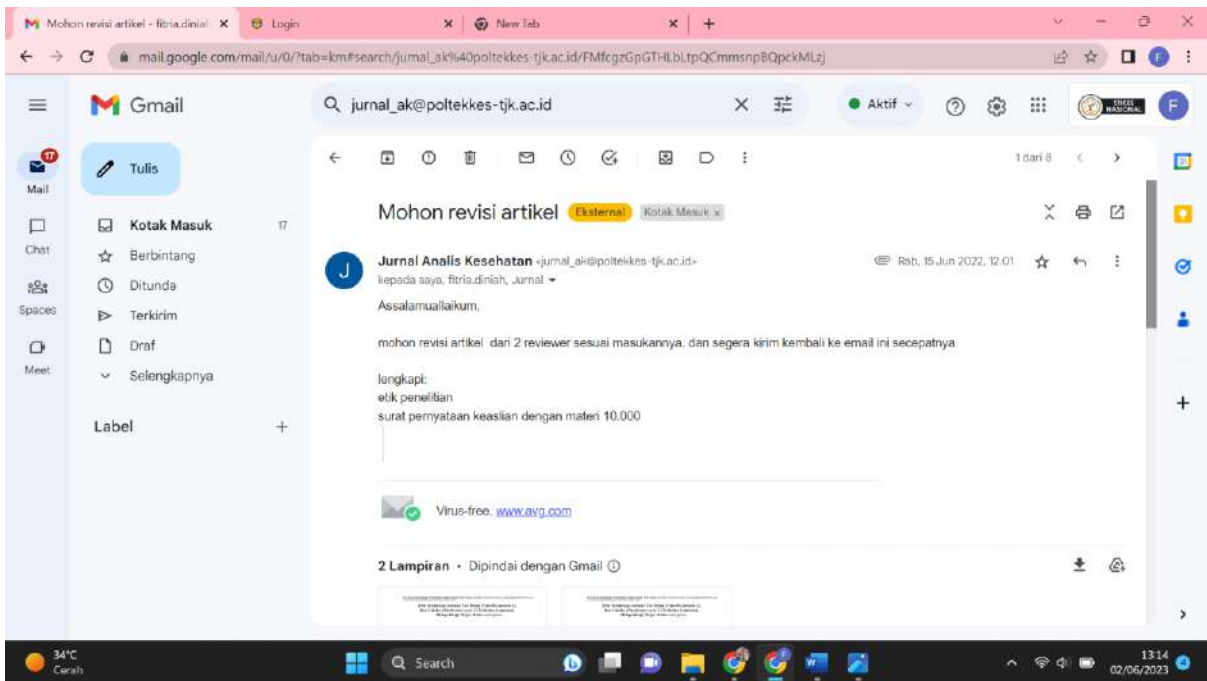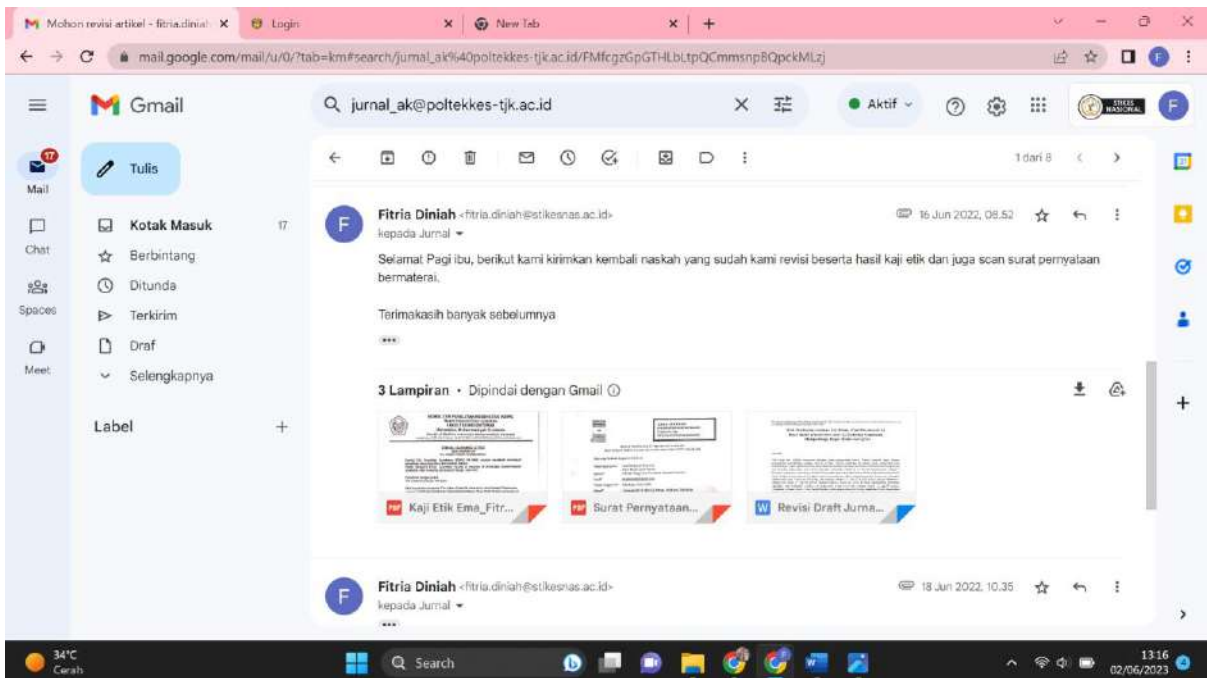
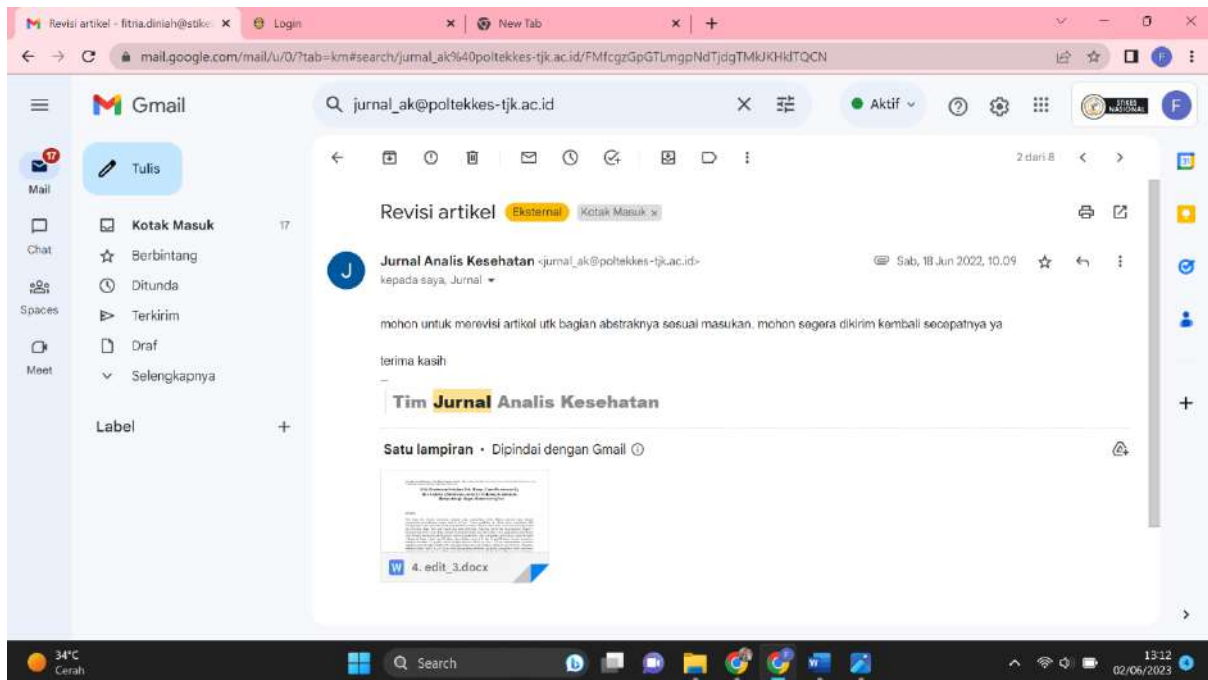


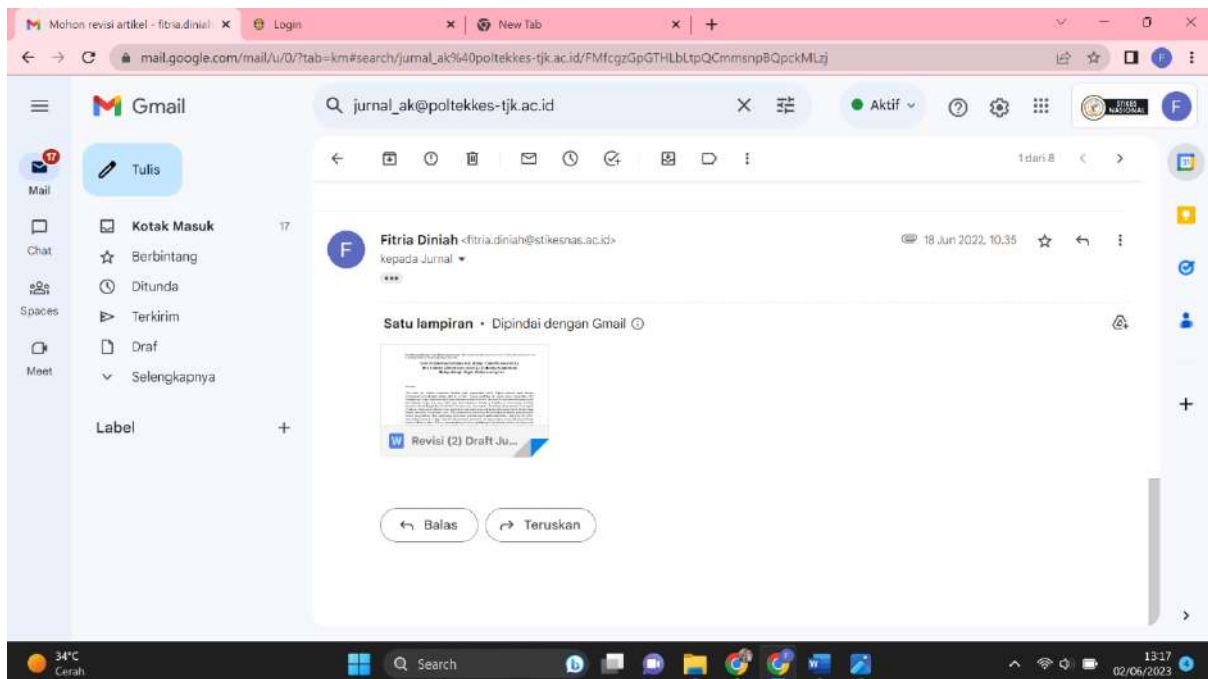
Proses revisi dari pengelola jurnal setelah submit



Proses pengiriman hasil kaji etik, surat pernyataan dan hasil revisi sesuai masukan reviewer



Permintaan revisi bagian abstrak kembali



Pengiriman hasil revisi kembali, Bukti pembayaran dan follow up selanjutnya dilaksanakan melalui Aplikasi Whatsup.

ejurnal.poltekkes-tjk.ac.id/index.php/JANALISKES/article/view/3153

**JURNAL ANALIS KESEHATAN**  
Politeknik Kesehatan Kementerian Kesehatan Tanjung Karang

ISSN (Cetak) 2252-3553  
ISSN (Online) 2623-0739

HOME ABOUT LOGIN REGISTER SEARCH CURRENT ARCHIVES ANNOUNCEMENTS

Home > Vol 11, No 1 (2022) > **Damairia**

### Efek Pemberian Seduhan Teh Hitam (*Camellia sinensis* L) Dan Cokelat (*Theobroma cacao* L) Terhadap Gambaran Histopatologis Hepar *Rattus norvegicus*

Ema Rochayani Damairia, Fitria Diniyah Janah Soyekti

#### Abstract

Black tea and chocolate are plants that contain caffeine. Chocolate is a commodity that generates foreign exchange for the country and is the main ingredient for making chocolate which also contains caffeine. Caffeine damages the liver by inhibiting the growth of connective tissue in liver cells. The purpose of this study was to determine the histopathological effect on the liver organs of white rats given black and chocolate tea steeping and the damage that occurs when given in a predetermined dose and time. The research was conducted experimentally at the Anatomical Pathology Laboratory of the Sekolah Tinggi Ilmu Kesehatan Nasional. The study was divided into 7 treatment groups. Liver organs were observed macroscopically and microscopically

ONLINE SUBMISSION  
CERTIFICATE  
Editorial Team  
Author Guidelines  
Peer-Reviewers

3025-11187-1-PB.pdf WhatsApp Image...jpeg PARASITOLOGI190...pdf scann\_02 (1).pdf Show all

34°C Cerah Search 13:16 02/06/2023

Artikel yang telah terbit di Jurnal Analis Kesehatan Vol 11 No 1 Juni 2022